



Ostomy Assessment Terms & Definitions

This assessment terms & definitions document provides the framework for standardized ostomy terminology to be used for documentation (paper and electronic) and for staff education.

Fecal Diversions: Surgically created diversions in either the small or large bowel to facilitate the evacuation of stool. Management of fecal continence done with an external pouching systems.	
Ileostomy	A portion of ileum, the last section of the small bowel, is brought through the abdomen and everted to create a stoma. Can be permanent or temporary.
Colostomy	A portion of colon is brought through the abdomen and everted to create a stoma. Can be permanent or temporary. There are four types of colostomies, named for the portion of colon used; ascending, transverse, descending or sigmoid.
Jejunostomy	A portion of jejunum, the middle section of the small bowel, is brought through the abdomen and everted to create a stoma. Can be permanent or temporary.
Cecostomy	A portion of cecum, the first section of the large bowel, is brought through the abdomen to create a skin-flush or everted small stoma. An alternative method is to put a tube through to the cecum as a permanent or temporary solution for decompression of the bowel. Can be permanent or temporary.

Urinary Diversions: Surgically created urinary diversion system which replaces the bladder and/or urethral functions. Management of urinary continence is done with an external pouching system.	
Urostomy	The surgically created abdominal opening of a urinary diversion.
Ileal Conduit	The ileum section of the small bowel is dissected; one end of the section is sutured closed, the open end is brought through the abdominal wall to skin surface and the ureters are implanted into the conduit (track). Continence is managed by an external pouching system.
Colon Conduit	Similar to the ileal conduit but a section of the large bowel (colon) is used to create a conduit (track). Continence is managed by an external pouching system. Rarely done.
Ureterostomy	The surgically created abdominal opening for a diversion of the ureters; both ureters may be brought up to the skin surface (two stomas) or one ureter may be anastomosed to the other and only one of the ureters is brought up to the skin surface. Continence is managed by external pouching system. Rarely done.

Surgical Plan	
Permanent	Bowel or urinary diversion is permanent.
Temporary	Bowel or urinary diversion is temporary and may be reversed at some point.
To Be Determined	Decision regarding permanent or temporary diversion yet to be determined.


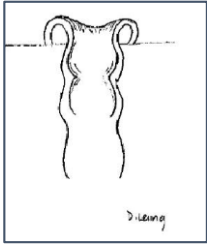

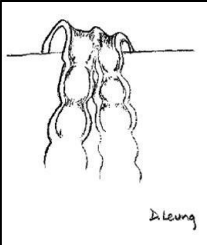

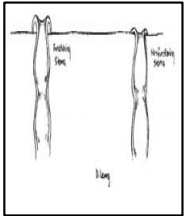
The following are parameters and assessment findings used when documenting an assessment of an ostomy, either in the post-op phase (up to 8 weeks post-surgery) or when the ostomy is established (after the post-op period).

Consider a *parameter* as an assessment question with an *assessment finding* being the answer to the question; in some cases there can be more than one finding.




Stoma Construction: Refers to how a stoma is surgically created. The stoma may be created from either the small bowel or colon (large bowel) by everting the incised bowel and suturing it to the surface of the skin. Can be either:

- **New:** first surgical construction of a stoma.
- **Revision:** surgical re-construction of the stoma.

<p>End</p> 		<p>An end stoma is created by incising the intestine and bringing the proximal end of the intestine through an opening in the abdominal wall to just above skin level.</p>
<p>Loop</p> 		<p>A loop stoma is created by mobilizing the side of the intestine up through an opening in the abdominal wall and making a transverse incision on the intestine. This stoma will have two openings, proximal and distal. A temporary supporting rod may be placed under the stoma to prevent stoma retraction.</p>
<p>Double Barrel</p> 		<p>A resection of the bowel is done; both the proximal end and the distal end are brought up through openings in the abdominal wall, creating two end stomas. The stomas can be positioned side by side or some distance apart.</p> <p>The proximal will be the functioning stoma and the distal is the non-functioning stoma - also known as a mucous fistula.</p>

Fistulas: may be surgically created or a spontaneous opening of the bowel.

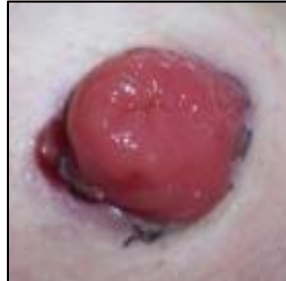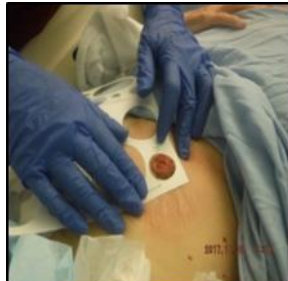<p>Mucous Fistula</p>	<p>Is a surgically created fistula, done as part of the creation of an ostomy, where the distal end of the remaining intestine is brought through the abdominal wall, everted and attached similar to the ostomy itself. Is considered “non-functioning” but may produce mucous which requires management.</p>
<p>Enterocutaneous Fistula</p> 	<p>An enterocutaneous fistula (ECF) is a spontaneous fistula which the body itself creates between the small intestine and the surface of the skin. Clients who have an ostomy due to Crohn’s Disease, Ulcerative Colitis or bowel radiation therapy are a high risk for developing a small bowel or bowel ECF.</p> <p>ECFs may appear at the stoma’s mucocutaneous margin, on the peri-ostomal skin or on surrounding skin and can cause significant pouching concerns.</p>



Stoma Size: Stomas vary in size due to many factors including location in the bowel, body habitus, edema, etc. A person's stoma can also change over time. It is important to know the size of the stoma before choosing the pouching system.

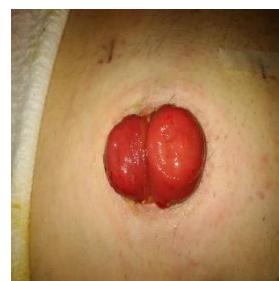Round

Use an ostomy measuring guide to find the correct diameter in millimeter (mm).



Oval

Measure length as the longest measurement and width as the widest area; perpendicular to the length.

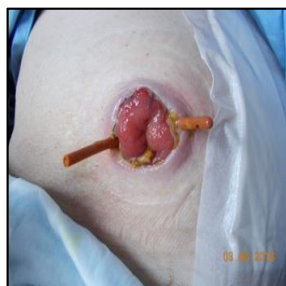
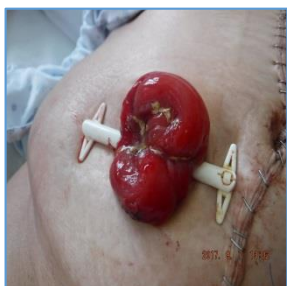
Devices in Situ: device used to support the initial healing phase.

Rod/Bridge

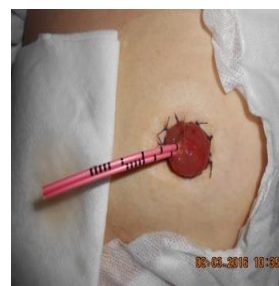
For those stomas constructed as loop, a device may be placed under the loop of intestine to provide support in order to prevent retraction of the stoma¹ during the early stage of stoma maturation (~ first 7 days).

This device may be a commercially available rod, a Penrose drain or red rubber catheter; may, or may not, be sutured.



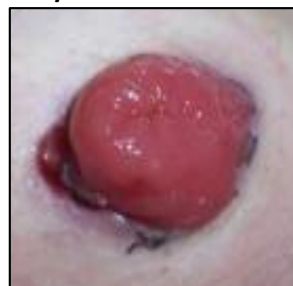Stents

A small plastic tube which sits in each of the ureters and exits through the stoma; used to divert urine while surgical anastomosis heals; usually short term.



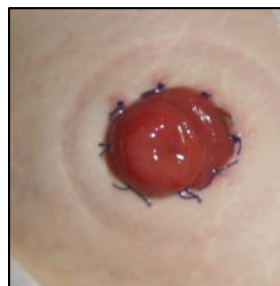Stoma Appearance: Stoma colour is usually pink/red and moist but appearance may vary depending on blood supply. Stoma tissue is fragile and bleeds easily with minimal contact. Red/pink, dusky, purple/maroon, slough and necrotic are to be documented as %, (e.g., 50% red/pink & 50% slough).

Red/Pink



Pink or red; healthy with normal/adequate blood supply. Warm to the touch.

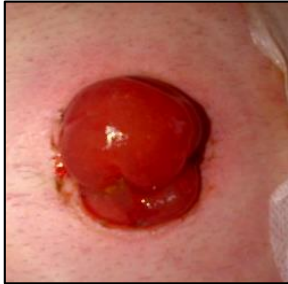Moist



Mucous tissue (mucosal) is moist.

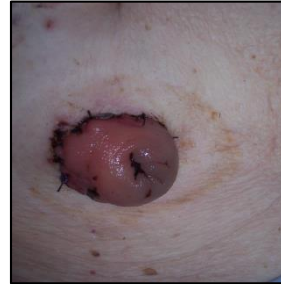Stoma Appearance: continued

Edematous



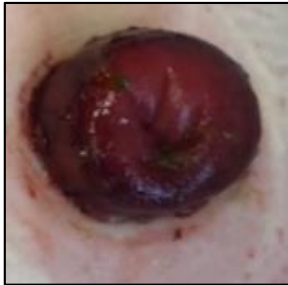
Shiny, swollen, translucent, smooth appearance; due to interstitial collection of fluid.

Dusky



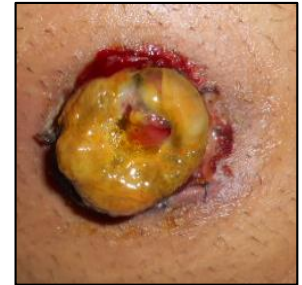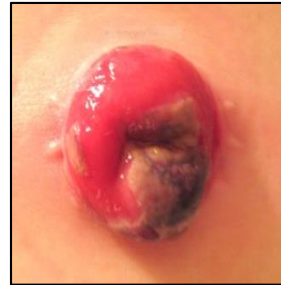Bluish hue due to altered blood supply. Cool to the touch.

Purple/Maroon

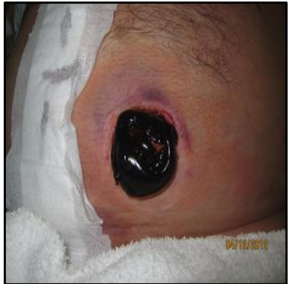

Purple to a deep wine colour due to altered blood supply. Cool to the touch.

Slough Loose or adherent moist, yellow devitalized tissue.

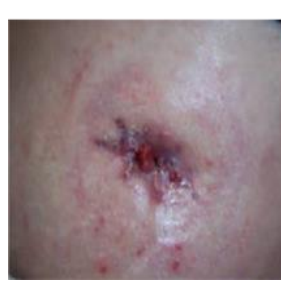

Necrotic



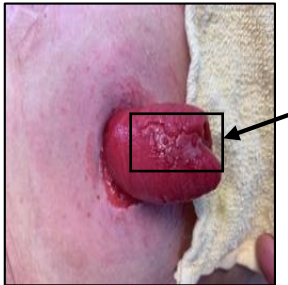
Loose to firmly adherent, darker-coloured devitalized tissue most likely related to ischemia.

Stenosed






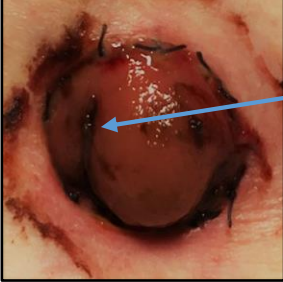
A narrowing of the stoma at level of the skin or fascia which can impair output.

Trauma







A cut, abrasion or bruise on the surface of the stoma.

Stoma Os: opening in the stoma which allows the passing of feces or urine.

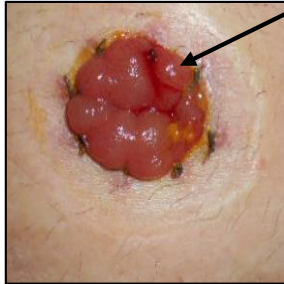
<p>Centered</p>  <p>Opening is in the center of the stoma.</p>	<p>Off-centered</p>  <p>Opening is positioned off-center.</p>
<p>Tilted</p>  <p>Opening is positioned centrally but the stoma itself is tilted.</p>	<p>Skin Level</p>  <p>Opening is level with peristomal skin.</p>

Stoma Height: a protrusion of approximately 2cm above skin level is ideal.

<p>Raised/Above Skin Level</p>  <p>Stoma sits above the level of the skin.</p>	<p>Flush/At Skin Level</p>  <p>Stoma sits at the same level of the skin.</p>
<p>Retracted/Below Skin Level</p>  <p>Stoma sits below the level of skin.</p>	<p>Prolapsed >2cm</p>  <p>Created by the outward telescoping of the bowel. Stoma length can be anywhere from 3cm to 60cm. The length of the prolapse can vary, related to patient position or activity e.g. may slide out when sitting but return to 'normal' length when standing up, or be a fixed length. The assessment should be done with the patient in different positions, lying flat, sitting and standing.</p>

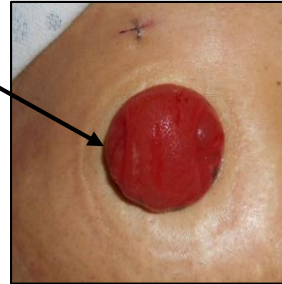
Mucocutaneous Junction: the point where the epidermis and the mucosa merge.

Intact with sutures



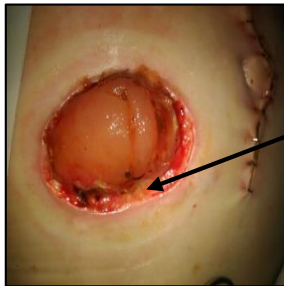
Mucocutaneous junction is well-approximated.

Intact fully epithelialized



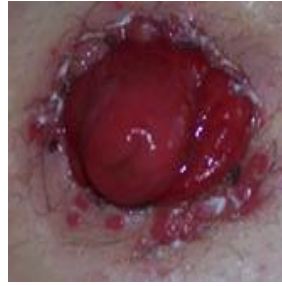Mucocutaneous junction is well-healed.

Separated



An area of detachment(s) of the stoma and skin (dehiscence).
The separation may be circumferential or partial.
Measuring separation is similar to measuring undermining in a wound; the face of the clock is used to describe the location, (e. g. 1 o'clock – 7 o'clock), and then measure all the depth and document the deepest depth found.

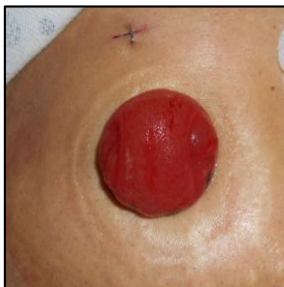Suture Granuloma



Hypergranulation of tissue most often over a suture.

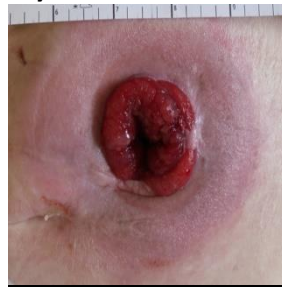Peristomal Skin: the skin under the pouching system.

Intact



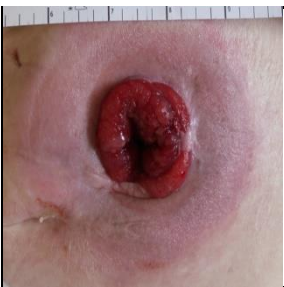Healthy skin which is not broken or discolored in comparison to the skin in the surrounding abdominal area.

Erythema



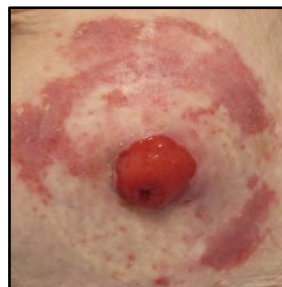Redness (**erythema**) of the skin may be intense, bright red to dark red.

Indurated



Abnormal firmness (**induration**) noted by touch of the tissue with palpable margins.

Excoriated

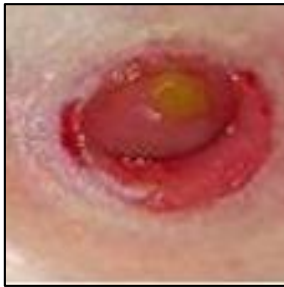

The loss or stripping of the epidermal layer from the presence of moisture or caustic substances



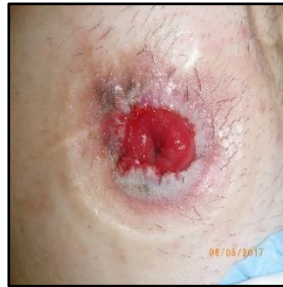Peristomal Skin continued

Denuded (Erosion)



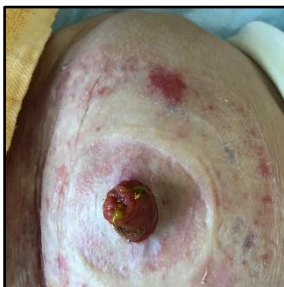
A common sign of severe Moisture Associated Skin Damage characterized by epidermal and dermal loss resulting in a partial thickness wound. May begin with islands of eroded skin and grow to a large area of denudation. Has a distinct perimeter of damage.

Macerated



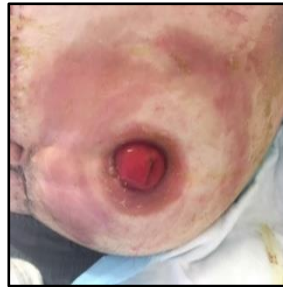Wet, white-looking skin.

MARSI



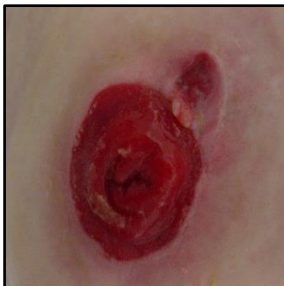MARSI = Medical Adhesive Related Skin Injury
A tear in the skin which occurs when the adhesive surface of the pouching system is removed, may be a Type 1, Type 2 or Type 3 Skin Tear.

Bruised



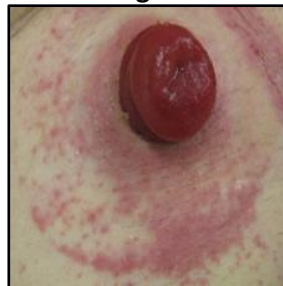Dark red, purplish-blue tissue that fades to yellow, green, or grey depending on the skin colour.

Wound



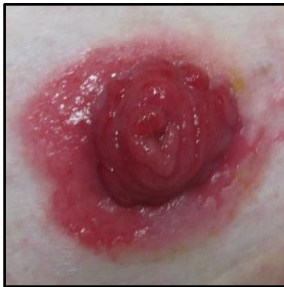Skin damage due to pressure, may be superficial or have measureable depth.

Rash - Fungal



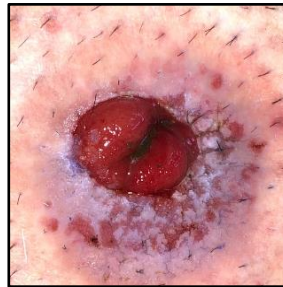
Overgrowth of fungal organisms that present as pustules on the skin. Satellite lesions (small red pustules) are often seen advancing from the edge of affected area.

Rash/Contact Dermatitis



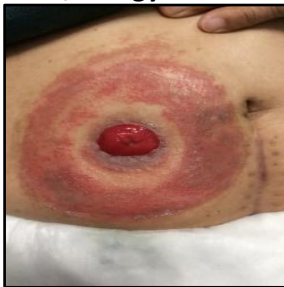Skin damage due to irritation of the skin from stool leakage

Rash/Folliculitis



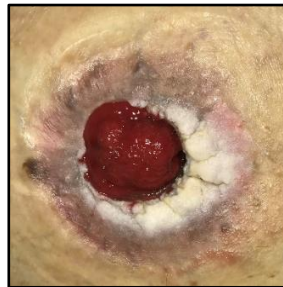Seen as red pustules and papules that are from bacterial inflammation of hair follicles.

Rash/Allergy







Skin damage due to irritation of the skin from adhesive material of the pouching system.

Pseudoverrucous Lesion





An overgrowth of benign papules that occur around the stoma due to chronic irritation of urine or stool.

Peristomal Skin continued

<p>Malignant Lesion</p>  <p>An area of abnormal looking tissue, may have an irregular surface e.g., cauliflower-like, and may be hard to the touch or friable. In appearance, is quite similar to hyper granulation.</p>	<p>Peristomal Psoriasis</p>  <p>Sharply defined patches of scaly red skin.</p>
<p>Pyoderma Gangrenosum</p>  <p>Recurrent, painful ulcerations which start as a pustule that rapidly progress to partial or full thickness wound, sometimes with dark-coloured irregular borders and purulent exudate.</p>	<p>Caput Medusae</p>  <p>Peri-stomal varices which are a manifestation of severe liver failure and portal hypertension.</p>

Abdominal Contours: Creases/folds and/or distension of the abdomen that affects the fit of a pouching system.

<p>Parastomal Hernia</p> 	<p>Usually seen in the sitting or standing position. Deficit in the fascia that allows a loop(s) of the intestine to protrude in an area of weakness in the peristomal area. Can present as an abnormal bump(s) on the abdomen.</p>
<p>Skin Crease/Fold</p> 	<p>A dip in the abdomen. The depth may vary from shallow to very deep.</p>
<p>Distended</p>	<p>Abnormal to patient, protruding of abdomen.</p>
<p>Flabby</p>	<p>Normal to patient, deep folds of skin.</p>
<p>Flat</p>	<p>Abdominal plane is flat.</p>
<p>Loose/Wrinkly</p>	<p>Abdomen has folds of loose skin.</p>
<p>Rounded</p>	<p>Normal to patient, abdominal plane is rounded.</p>
<p>Pendulous</p>	<p>Abdominal tissue hanging loosely.</p>
<p>Soft</p>	<p>Abdomen is soft with palpation.</p>
<p>Hard</p>	<p>Abdomen is firm or hard with palpation.</p>



Specific Pouching Concerns	
Parastomal Hernia	See above page 8.
Skin Crease/Fold	See above page 8.
Rounded Abdomen	See above page 8.
Stoma Flush	See above page 5.
Stoma Retracted	See above page 5.
Stoma Prolapse	See above page 5.
Stoma Os Tilted	See above page 5.
Proximity Incision	Close to abdominal incision.
Proximity Drain	Close to abdominal drain.
Proximity Umbilicus	Close to umbilicus.
Proximity Wound	Close to abdominal wound.
Proximity Bony Prominence	Close to iliac crest.

Output Characteristics			
Stool		Urine	
Characteristics	Colour	Characteristics	Colour
<ul style="list-style-type: none"> • Flatus • Mucous • Watery • Mushy • Pasty • Semi-formed • Formed • Hard 	<ul style="list-style-type: none"> • Brown • Yellow • Green • Clay • Black • Bloody 	<ul style="list-style-type: none"> • Clear • Concentrated • Mucous shreds • Cloudy • Clots • Sediment • Malodorous (foul smelling) 	<ul style="list-style-type: none"> • Pale Yellow • Yellow • Amber • Orange • Pink • Red

Pouching Systems: containment devices for both stool and urine.	
1-piece (fecal or urine)	The adhesive flange and the pouch are fused together as one piece.
2-piece (fecal or urine)	Comes as two separate pieces, an adhesive flange, which is applied to the surface of the skin, and a pouch which is attached to the flange.
Flat (fecal or urine)	Adhesive flange designed as a flat surface.
Convex (fecal or urine)	Adhesive flange designed with convexity around the opening; comes in varying degrees of convexity and either soft or hard convexity.
Drainable Pouch (fecal or urine)	A pouch designed with an opening at its end to allow for stool or urine to be emptied from the pouch. Fecal pouch closure devices are either a clip or clamp; urostomy pouches have a spigot. Pouch is reusable for the duration of the flange wear-time.
Closed-end Pouch (fecal colostomy only)	A fecal pouch with no opening; the pouch is removed following a bowel movement and new pouch is attached to the flange or a new one-piece system is applied.

Pain with pouching change: client to rate any pain related to pouching change on a scale of 0-10 with 10/10 being the worse pain



Bibliography

1. Wound, Ostomy, Continence Nurses Society, Carmel, J.E., Colwell, J.C. & Goldberg, M.T. (2015). Wound, ostomy and continence nurses' society core curriculum: Ostomy Management. Lippincott Williams & Wilkins.
2. Wound, Ostomy, Continence Nurses Society, Doughty, D. & McNichol, L. (2015). Wound, ostomy and continence nurses' society core curriculum: Wound Management. Lippincott Williams & Wilkins.
3. Wound, Ostomy, Continence Nurses Society (2017). Clinical guideline: Management of the adult patient with a fecal or urinary ostomy. Mt. Laurel, NJ: Publisher.
4. DermNet NZ. <https://dermnetnz.org/topics/terminology> (last accessed June 5th, 2021).

Document Creation/Review

This document is based upon the best information available at the time it was published and relies on evidence and avoids opinion-based statements where possible.

Created By	British Columbia Provincial Nursing Ostomy Committee in collaboration with NSWOCs from all Health Authorities
Publication Date	September 2022
Revision Date(s)	
Review Date (s)	